0022-5347/99/1623-0990/0
THE JOURNAL OF UROLOGY
Vol. 162, 990–994, September 1999
Copyright © 1999 by AMERICAN UROLOGICAL ASSOCIATION, INC.
Printed in U.S.A.

LAPAROSCOPIC FOWLER-STEPHENS ORCHIOPEXY FOR THE HIGH ABDOMINAL TESTIS

BRUCE W. LINDGREN, ISRAEL FRANCO, SHAWN BLICK, SELWYN B. LEVITT, WILLIAM A. BROCK, LANE S. PALMER, STEVEN C. FRIEDMAN AND EDWARD F. REDA

From the Long Island Jewish Medical Center-Schneider Children's Hospital, New Hyde Park and Westchester Medical Center, Valhalla, New York, and Loyola University Medical Center-Stritch School of Medicine and Ronald McDonald Children's Hospital, Maywood, Illinois

ABSTRACT

Purpose: Laparoscopic orchiopexy is extremely effective for treating patients with nonpalpable testis. However, despite the high dissection and wide mobilization it allows in some cases, vessel length prevents the testis from reaching the scrotum. There have been only incidental cases reported in which laparoscopy has been used for vessel transection and testicular mobilization orchiopexy. We reviewed our cases treated with the Fowler-Stephens orchiopexy performed laparoscopically in 1 or 2 stages.

Materials and Methods: We reviewed the records of all boys who underwent laparoscopy for a nonpalpable testis at our institutions since 1992. Patients who underwent testicular vessel transection and orchiopexy performed laparoscopically in 1 or 2 stages were selected for evaluation. Office charts and operative reports were reviewed in detail.

Results: Of the 126 nonpalpable testes in 108 patients 51 (40%) were intra-abdominal, including 18 (35%) in 14 patients in whom the Fowler-Stephens procedure was performed laparoscopically. Five testes were treated with a 2-stage procedure, while 11 were managed by laparoscopic mobilization followed by laparoscopic vessel clipping and orchiopexy in 1 stage. In 2 additional patients nearly all dissection was performed laparoscopically but due to extenuating circumstances inguinal incision was required as well. Thus, 13 testes were managed by 1-stage Fowler-Stephens orchiopexy, including all cases since August 1996 which required vessel transection. Two patients were hospitalized postoperatively for prolonged ileus after the second stage. All other 2-stage and all 1-stage cases were managed on an outpatient basis. There were no complications. At a mean followup of 6 months all cases without previous surgery that were managed by laparoscopic orchiopexy are without atrophy and the testes are in a scrotal position. Two testes in which previous surgery had been done atrophied postoperatively.

Conclusions: Laparoscopic transection of the testicular vessels is safe in boys with high abdominal testes that do not reach the scrotum after laparoscopic high retroperitoneal dissection. The magnification and wide mobilization of laparoscopy likely allow better preservation of the collateral vascular supply than open exploration. Previous surgery is a risk factor for atrophy. The success rate of 89% overall and 100% in patients who did not previously undergo testicular surgery equals or exceeds that of open orchiopexy in patients with abdominal testes. The 1-stage procedure avoids repeat anesthesia and the extensive, sometimes tedious, dissection that is occasionally required during reoperation.

KEY WORDS: testis, abnormalities, cryptorchidism, laparoscopic surgical procedure

Treatment of the patient with a nonpalpable testis continues to evoke controversy among pediatric urologists. Difficult mobilization as well as significant complications, including atrophy, have led to a multitude of approaches to this dilemma. Open ligation of the testicular vessels performed in 1 or 2 stages has an overall success rate of only 67 to 77%, respectively.[1] Laparoscopic orchiopexy was initially described in 1992 by Jordan et al[2] and since that time it has gained considerable support. It is extremely effective for managing nonpalpable testis and recent data indicate a success rate of 96% for scrotal placement and no cases of testicular atrophy.[3] Its advantages include the diagnosis of the presence or absence of a testis at the diagnostic stage, high retroperitoneal dissection and magnification, which aids in preserving the vascular supply. Nevertheless, in some cases of high abdominal testis vessel length prevents the testis from reaching the scrotum despite wide mobilization during an open or laparoscopic procedure.

Bloom initially reported using laparoscopy to ligate the spermatic vessels as stage 1 of the Fowler-Stephens procedure[4] with stage 2 performed via an open approach. Since then, laparoscopy used for vessel ligation, testicular mobilization and orchiopexy in an individual has been reported only incidentally.[3,5,6] Therefore, we reviewed our series of patients treated with laparoscopic Fowler-Stephens orchiopexy in 1 or 2 stages.

METHODS

We retrospectively reviewed the records of all boys who underwent diagnostic laparoscopy for a nonpalpable testis at Long Island Jewish Medical Center-Schneider Children's Hospital and Westchester Medical Center. These cases were identified by querying our computerized database of records, which dates back to 1992. Patients who underwent testicular vessel transection and orchiopexy laparoscopically in 1 or 2

stages were selected for evaluation. Office records and operative reports were reviewed in detail.

Our technique of laparoscopic orchiopexy has been reported previously.[3] Briefly the patient is positioned supine with the legs abducted. The abdomen, groin and genitalia are prepared, and the stomach and bladder are decompressed. A curvilinear subumbilical incision is made and the abdominal fascia is identified. Stay sutures are placed into the fascia with 2-zero polyglactin suture to allow elevation of the abdominal wall. The peritoneum is identified and opened, and a 5 mm. sheath is inserted under direct vision. After carbon dioxide insufflation at 12 mm. Hg the abdomen is inspected for a testis on the affected side. If an abdominal testis is identified, we proceed with laparoscopic orchiopexy (fig. 1).

Two accessory ports are placed at approximately the umbilical level in the midclavicular line on either side of the abdomen. The gubernacular attachments are grasped and transected as far distally as possible using electrosurgical instruments. Dissection proceeds by incising the peritoneum caudal to the vas deferens and then lateral to the spermatic vessels. At the superior extent of dissection the peritoneum overlying the spermatic vessels is incised, taking care to avoid injuring the artery or vein. This step serves to free the testicular vessels from the posterior peritoneal attachments and it often provides additional length. After this is completed one should be able to determine whether the spermatic vessels are of sufficient length to allow placement of the testis in the dependent portion of the scrotum. If there is any question, the testis is brought as far down as possible via a scrotal trocar through the neohiatus, which is positioned medial to the medial umbilical ligament and just over the pubic tubercle. If the testis reaches the scrotum without tension at this time, orchiopexy is performed by placing the testis in a subdartos pouch for standard laparoscopic orchiopexy (fig. 2, *A*). If there is insufficient length to place the testis in the dependent portion of the scrotum, the vessels may easily be clipped and divided at this time (fig. 2, *B*). The testis is then fixed in position in the subdartos pouch.

Because the initial dissection is the same whether vessel transection is required or not, we did not try to predict which testes would require vessel transection based on laparoscopy only. Generally testes located at or proximal to the iliac vessels were most likely to require the Fowler-Stephens procedure. In addition, older boys were more likely to require vessel transection even when the testis was more distal and near the internal inguinal ring.

FIG. 1. Laparoscopic view of left intra-abdominal testis

RESULTS

We identified 126 nonpalpable testes in 108 patients, of which 51 (40%) were intra-abdominal (table 1). Of the 51 intra-abdominal testes 18 (35%) in 14 patients were identified in which the Fowler-Stephens procedure had been performed laparoscopically. Five boys had left, 2 had right and 7 had bilateral nonpalpable testes. Of the 7 patients with bilateral nonpalpable testes 3 underwent inguinal or laparoscopic orchiopexy of 1 testis with laparoscopic Fowler-Stephens orchiopexy of the other using the same anesthetic. Thus, 7, 3 and 4 boys with left, right and bilateral testes, respectively, were treated with laparoscopic Fowler-Stephens orchiopexy. Of the bilateral cases a bilateral 2-stage procedure (2 operations) was done in 1, a 1-stage Fowler-Stephens procedure on 1 side and a 2-stage procedure on the contralateral side (2 operations) in 2 and bilateral laparoscopic Fowler-Stephens orchiopexy as a single operation in 1. Mean patient age at surgery was 44 months (range 11 to 120).

Five intra-abdominal testes were managed as 2-stage procedures with laparoscopic clipping and transection of the testicular vessels, followed by laparoscopic orchiopexy approximately 6 months later. In 4 cases the vessels were clipped and the testis remained undisturbed during stage 1. In 1 case limited mobilization of 1 testis was performed. A decision was then made to complete orchiopexy as a staged procedure and the vessels were clipped. At stage 2 the testis was fixed to the medial umbilical ligament with dense scar tissue from theprevious mobilization. Tedious laparoscopic dissection was required to complete stage 2.

A 1-stage procedure was done in 13 testes, of which 11 involved laparoscopic mobilization of the testis, laparoscopic vessel ligation and orchiopexy done in 1 setting. Two patients underwent laparoscopic mobilization of the intra-abdominal testis but due to extenuating circumstances they also required inguinal incision. In 1 boy the testis was mobilized completely via laparoscopy, and it was determined that the vessels were not long enough to allow placement in the dependent portion of the scrotum without vessel division. Although the endoscopic clip applier was inserted, it malfunctioned and an inguinal incision was made to ensure adequate ligation of the testicular vessels. In the other patient inguinal exploration had been done elsewhere for presumed torsion of an intra-abdominal testis. The testis was not torsed, and the surgeon opted not to bring it down at that time. The patient then presented to our institution and underwent standard laparoscopic orchiopexy of the left testis, followed by laparoscopic mobilization of the right testis, vas and vessels to the extent allowed. Despite laparoscopic mobilization of the majority of the right testis and cord structures the epididymis was entrapped in dense scar tissue at the internal inguinal ring due to the previous exploration. Therefore, an inguinal incision was made, the epididymis was dissected free of surrounding scar tissue, the vessels were divided and orchiopexy was completed.

At a mean followup of 6 months all testes are in a scrotal position. In the 2 testes that were atrophied at followup previous surgery had been performed, including mobilization at stage 1 in 1 and exploration done elsewhere in 1. The remaining 16 testes were in a dependent scrotal position with normal consistency and none has atrophied (89% success, table 2). There were no other intraoperative or postoperative complications. Two patients required hospital admission postoperatively for an ileus after a second stage procedure.

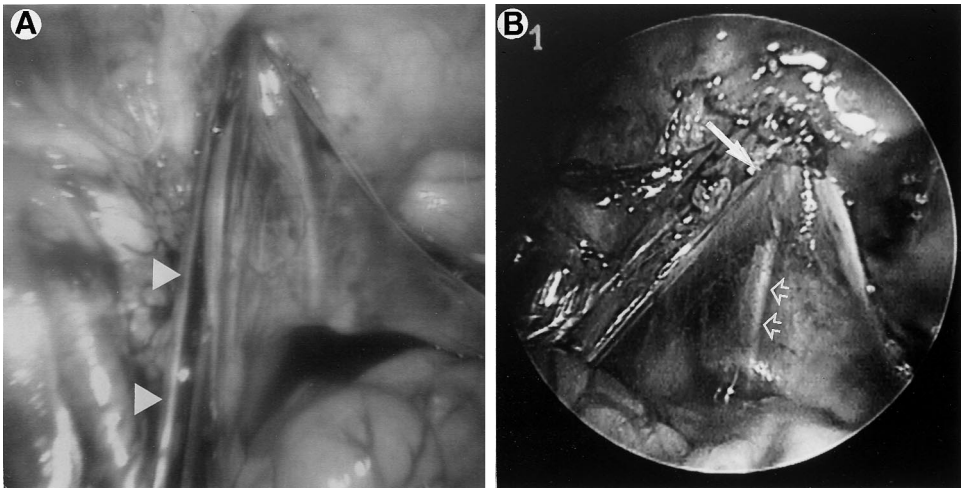

FIG. 2. *A*, left vas deferens and spermatic vessels exit neohiatus after standard laparoscopic orchiopexy. Note wide triangle of peritoneum preserved between vas and vessels (arrowheads). *B*, left vas deferens exits neohiatus after 1-stage laparoscopic Fowler-Stephens orchiopexy. Note clip on spermatic vessels (arrow), vasal vessels (open arrows) and wide triangle of peritoneum preserved between vas deferens and stump of spermatic vessels.

TABLE 1. *Surgical management of intra-abdominal testes*

	No. Pts. (%)
Laparoscopic findings:	
Nonpalpable testis	126 (100)
Intra-abdominal testis	51 (40)
Procedure:	
Laparoscopic orchiopexy	26 (51)
Open orchiopexy	4 (8)
Other	3 (6)
Laparoscopic Fowler-Stephens	18 (35)

TABLE 2. *Success of laparoscopic Fowler-Stephens orchiopexy*

Procedure	No. Pts./Total No. (%)	No. Pts. No Previous Testicular Surgery/Total No. (%)
1 Stage	12/13 (92)	12/12 (100)
2 Stage	4/5 (80)	4/4 (100)
Combined	16/18 (89)	16/16 (100)

All other 2-stage and 1-stage cases were managed on an outpatient basis.

DISCUSSION

The success rate of laparoscopic Fowler-Stephens orchiopexy performed in patients who have not undergone previous testicular surgery is 100% in our series, whether orchiopexy was done in 1 or 2 stages (table 2). The testes atrophied only after previous testicular surgery. There were no other postoperative and no intraoperative complications.

The multitude of approaches to and procedures for nonpalpable testis attests to the management dilemma it presents. When deciding which approach to use, one must consider the success rate of the procedure as well as morbidity or potential morbidity. We previously reported our preference for and success with diagnostic laparoscopy for the patient with nonpalpable testis with extension of the procedure to laparoscopic orchiopexy when a testis is identified at or proximal to the internal inguinal ring.[3] This approach was supported by Cisek et al, who recently reported that localization via diagnostic laparoscopy aided in planning the approach to a nonpalpable testis in 66% of patients.[7] Nevertheless, Kirsch et al prefer the inguinal approach in all of these patients.[8] Regardless of the open or laparoscopic approach to the nonpalpable testis, there remains a subset of patients in whom short testicular vessels associated with a high abdominal testis do not allow testis placement in the scrotum without division of the vessels.

This scenario is not new and all pediatric urologists are familiar with the numerous procedures available to treat these patients, including staged orchiopexy, transperitoneal or retroperitoneal orchiopexy via an extended inguinal or Pfannenstiel incision, Fowler-Stephens orchiopexy in 1 or 2 stages, microvascular transplantation and laparoscopic vessel clipping followed several months later by extended inguinal or transabdominal orchiopexy. However, Docimo reported that the success rates of these procedures range from as low as 67% for the 1-stage Fowler-Stephens procedure to 84% for microvascular orchiopexy,[1] which leaves room for improvement. In our current series laparoscopic management of these testes yielded success in 16 of 18 cases (89%), which to our knowledge has only been surpassed to date by the series of Koff and Sethi of low division of the spermatic vessels (93% of testes viable at 1 year).[9] However, when patients who previously underwent testicular surgery are excluded from analysis, the success rate of laparoscopic Fowler-Stephens orchiopexy in our series is 100%.

Our patient cohort is comparable to others in the current literature. We reported that 40% of nonpalpable testes were in an intra-abdominal location, while Cisek et al reported that 37% were intra-abdominal.[7] This disparity of 8 to 20%[8] is likely due to increased awareness of the importance of careful examination using anesthesia before laparoscopy and, therefore, the inclusion of fewer inguinal testes in contemporary reports.

The older age of our patients is notable and likely represents referral patterns in our area. We do not recommend waiting until patients are older to perform orchiopexy and we have done laparoscopic orchiopexy in patients as young as 6 months. Anecdotally we have noted that division of the spermatic vessels is more likely in older than in younger patients, which is suggested by the fact that in our series mean age of all patients treated with laparoscopic orchiopexy was only 39 months,[3] whereas those requiring vessel ligation were somewhat older (mean age 44 months, range up to 10 years).

When diagnostic laparoscopy is combined with 1-stage laparoscopic surgery in these patients, it allows the diagnosis and treatment in 1 setting and, thus, 1 anesthesia. This factor is the most compelling reason to perform the 1-stage procedure, since the success rate is the same in cases with no previous surgery whether performed in 1 or 2 stages (table 2). The laparoscopic approach also eliminates the need for an extended inguinal or Pfannenstiel incision, leading to de-

creased postoperative pain. Although this aspect is not addressed in some of the literature on the subject, clearly some patients require overnight hospitalization after extensive transabdominal exploration. The only 2 patients in our series who required hospital admission underwent 2-stage procedures and 1 had the prune-belly syndrome. All other patients were discharged home the day of the procedure. This is another factor that supports the 1-stage over the 2-stage procedure.

The only patients in our series in whom the testis atrophied after laparoscopic Fowler-Stephens orchiopexy had undergone previous testicular surgery. At the procedure it was noted that the vessels were too short to allow scrotal placement and division of the testicular vessels was required in each case. In 1 boy the epididymis was encased in scar at the level of the internal inguinal ring due to previous inguinal exploration, necessitating mobilization and obviously interfering with the collateral blood supply to the testis. Ultimately this condition resulted in testicular atrophy. The other case of atrophy underlines the advantage of the 1-stage laparoscopic Fowler-Stephens procedure. In this patient treated early in our series there was limited testicular mobilization during stage 1. Scarring due to stage 1 caused difficult dissection at stage 2. Since that time, we mobilize completely and divide the vessels only when the testis does not reach the scrotum, avoiding the need to repeat testicular mobilization later. This risk factor for atrophy is not unique to laparoscopy. As in any approach, dissection that interferes with the vasal blood supply in the setting of a Fowler-Stephens procedure places the testis at risk for atrophy.

A criticism of the standard Fowler-Stephens procedure is that it requires the surgeon to judge early in the case whether the vessels must be divided, especially during a 2-stage approach with open or laparoscopic ligation. In that setting one must commit to transection of the testicular vessels even before testing whether the testis reaches the scrotum without vessel division. Since our approach has evolved with experience, we now perform all of the extensive retroperitoneal dissection and attempt to bring the testis to the scrotum. We divide the vessels only when it is proved that the testis does not reach the scrotum. Since dissection in laparoscopic orchiopexy preserves the peritoneal window between the testicular and vasal vessels (fig. 2), dissection and mobilization are the same with or without vessel division. This approach may ultimately decrease the number of transections required and, as our results show, it produces results that equal those of the 2-stage laparoscopic approach and exceed traditional open 1 or 2-stage transection.[1,8]

This approach is similar in concept to the Koop orchiopexy, as reported by Kirsch et al.[8] They stated that extended intra-abdominal mobilization of the vas and vessels was performed from the retroperitoneal endopelvic fascia by incising and lifting the posterior peritoneum for extended dissection of the vessels under direct visualization. When the testis did not reach the scrotum after this dissection, they then divided the vessels. This initial dissection and attempt to bring the testis to the scrotum before committing to division of the vessels are conceptually identical to the dissection method of the 1-stage laparoscopic procedure in our series. Using the Koop technique 57 and 16% of the testes in the series of Kirsch et al were brought to the scrotum without division of the vessels from 1990 to 1994 and 1986 to 1990, respectively, with excellent results in 82%. Division of the vessels after this mobilization method was required in 28 patients (62%) from 1986 to 1990 and in 10 (22%) from 1990 to 1994. However, 26% of their patients had testicular atrophy after the open Fowler-Stephens procedure and in another 11% the testis was in a high scrotal position. The greater degree of success with the laparoscopic Fowler-Stephens procedure in our series may have been associated with leaving a wider peritoneal window intact when laparoscopy was done. Another potential explanation is that magnification used during laparoscopy may lead to better preservation of small collateral vasculature.

The laparoscopic approach is also supported by the fact that diagnostic laparoscopy aids in planning the approach in 66% of patients with a nonpalpable testis, and it provides useful information in regard to the presence, position and anatomy of vessels and vas in all cases of precanalicular testis.[7] The logical next step is to extend this from a diagnostic to a therapeutic modality. When all reported series of laparoscopic orchiopexy are combined, the success rate is 96%[3] with or without division of the spermatic vessels, which is comparable to the 97% success rate without division of the vessels for the Koop procedure.[8] Although the number of patients in our series is relatively small, our excellent success rate makes this a sound alternative to the open procedure in patients with an abdominal testis when vessel length necessitates division to achieve scrotal placement.

CONCLUSIONS

Laparoscopic transection of the testicular vessels is safe in boys with high abdominal testis that does not reach the scrotum after laparoscopic high retroperitoneal dissection. The magnification and wide mobilization of laparoscopy likely allow better preservation of the collateral vascular supply, accounting for the improved success rates over open exploration with or without vessel transection. Previous testicular surgery represents an increased risk for atrophy after division of the testicular vessels.

The overall success rate of 89% in our study is comparable to or exceeds that of open orchiopexy for abdominal testis. The 100% success rate of laparoscopic Fowler-Stephens orchiopexy done at 1 or 2 stages in patients who did not previously undergo testicular surgery is superior to the results of any series of open orchiopexy for abdominal testis using a 1 or 2-stage procedure.[1,8] Although the number of patients in our series is relatively small, our excellent success rates make this a sound alternative to the open procedure. A 1-stage laparoscopic Fowler-Stephens orchiopexy avoids repeat anesthesia as well as the potential for extensive, sometimes tedious, dissection that is occasionally required during reoperation.

REFERENCES

1. Docimo, S. G.: The results of surgical therapy for cryptorchidism: a literature review and analysis. J. Urol., **154:** 1148, 1995.
2. Jordan, G. H., Robey, E. L. and Winslow, B. H.: Laparoendoscopic surgical management of the abdominal/transinguinal undescended testicle. J. Endourol., **6:** 159, 1992.
3. Lindgren, B. W., Darby, E. C., Faiella, L., Brock, W. A., Reda, E. F., Levitt, S. B. and Franco, I.: Laparoscopic orchiopexy: procedure of choice for the nonpalpable testis? J. Urol., **159:** 2132, 1998.
4. Bloom, D. A.: Two-step orchiopexy with pelviscopic clip ligation of the spermatic vessels. J. Urol., **145:** 1030, 1991.
5. Jordan, G. H. and Winslow, B. H.: Laparoscopic single stage and staged orchiopexy. J. Urol., **152:** 1249, 1994.
6. Poppas, D. P., Lemack, G. E. and Mininberg, D. T.: Laparoscopic orchiopexy: clinical experience and description of technique. J. Urol., **155:** 708, 1996.
7. Cisek, L. J., Peters, C. A., Atala, A., Bauer, S. B., Diamond, D. A. and Retik, A. B.: Current findings in diagnostic laparoscopic evaluation of the nonpalpable testis. J. Urol., **160:** 1145, 1998.
8. Kirsch, A. J., Escala, J., Duckett, J. W., Smith, G. H. H., Zderic, S. A., Canning, D. A. and Snyder, H. M., III: Surgical management of the nonpalpable testis: the Children's Hospital of Philadelphia experience. J. Urol., **159:** 1340, 1998.
9. Koff, S. A. and Sethi, P. S.: Treatment of the high undescended testes by low spermatic vessel ligation: an alternative to the Fowler-Stephens technique. J. Urol., part 2, **156:** 799, 1996.

DISCUSSION

Dr. Jeffrey Wacksman. This series is good but it is small. We used a laparoscopically assisted testicular autotransplant. Dr. Steven G. Docimo reviewed our data with good results. A word of caution: if you have a patient with bilateral intra-abdominal testes and you are going to do a Fowler-Stephens procedure, and 1 side goes beautifully and you think everything looks great when you get it down, do not clip the other side at the same time. We treated 2 patients in whom this happened. Clipping the other side at the same time you are doing the primary side negates the ability to do any type of autotransplant if the initial side atrophies.

Dr. Richard Ehrlich. Have you ever mentioned to parents the necessity of the child not undergoing vasectomy when he grows older?

Dr. Bruce Lindgren. I have not mentioned that to them but that is a good point that should be considered, because that involves the whole blood supply to the testis.

Doctor Ehrlich. If you tell them, it should be written down, so that it is documented for medicolegal reasons.

Dr. Craig A. Peters. I would be cautious with this approach. After the report of Koff and Sethi a few years ago challenging the value of 2-stage orchiopexy (reference 9 in article), we started doing opposite 2-stage and primary Fowler-Stephens orchiopexy. In our first 3 cases of the Fowler-Stephens procedure, clipping and moving the testis in 1 setting, 2 testes atrophied. Maybe that was just bad luck but I abandoned that technique. Your results look good. We all have to be cautious in regard to outcomes assessment but I would be hesitant to recommend this widely as yet. Our experience was not positive when doing it this way.

Dr. Antoine E. Khoury. What do you do with the original native internal ring? Do you think that there is any need to close it? I have not been closing it.

Doctor Lindgren. We have not either. I have not had any patient come back with a hernia.